

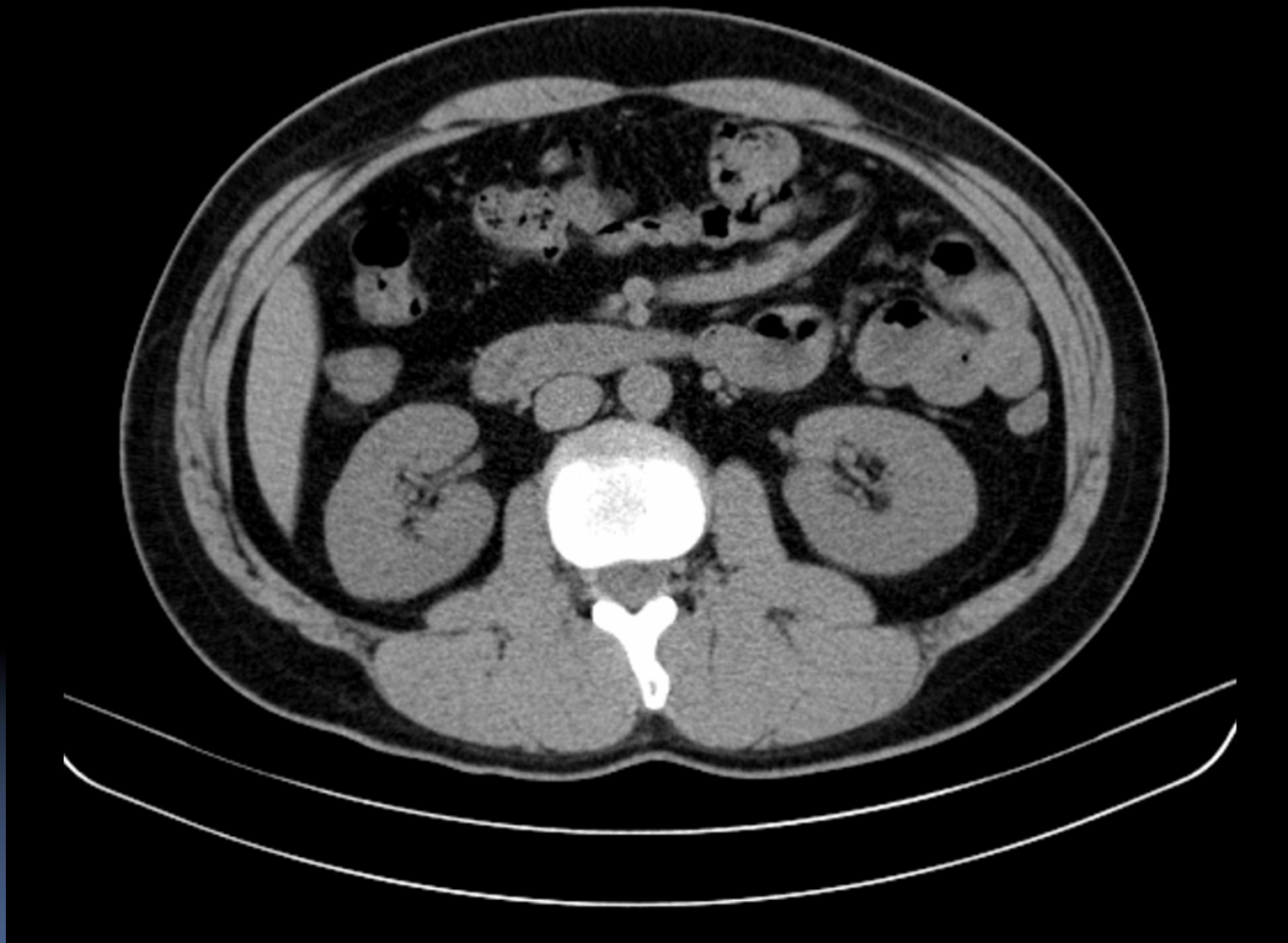图 1 腹部非造影CT

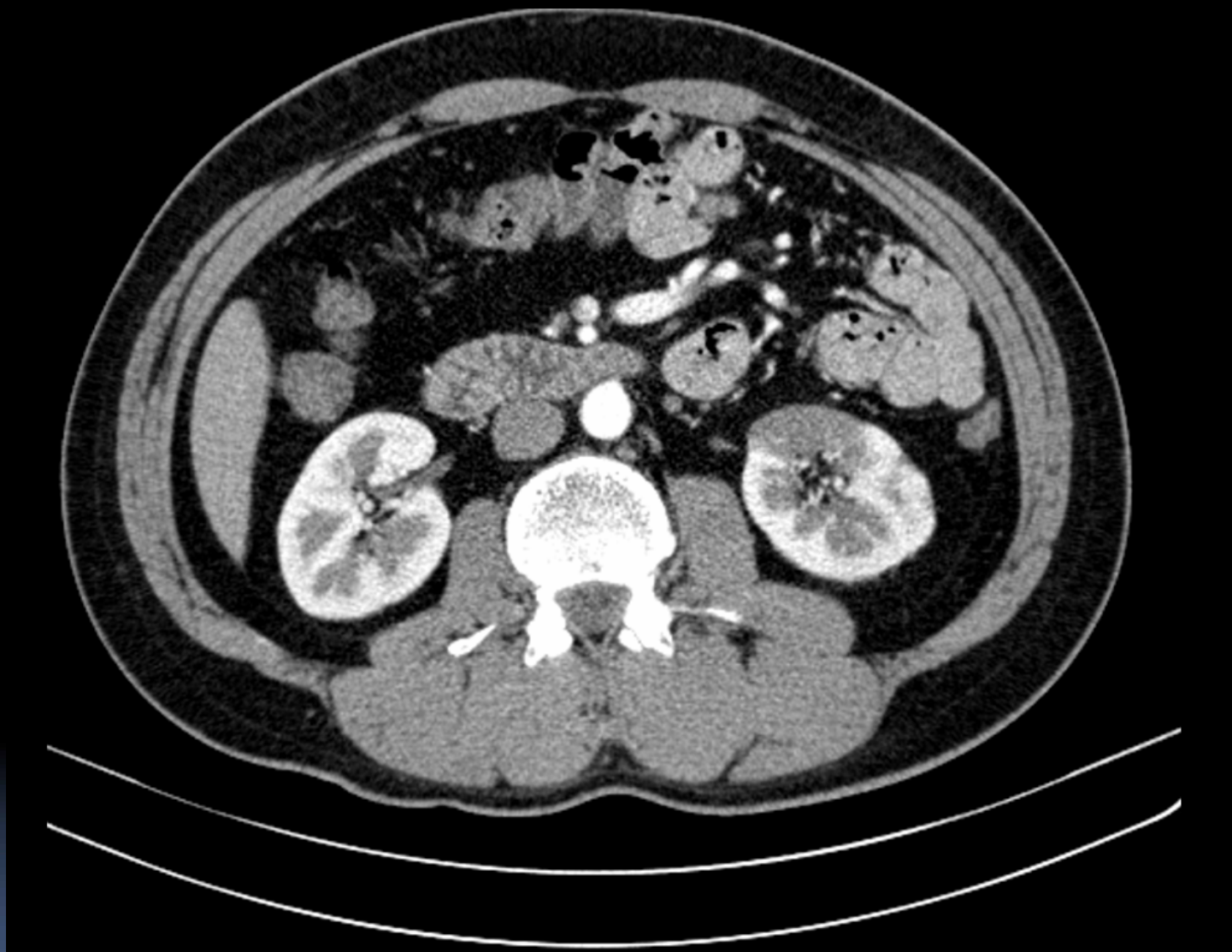


図 2 腹部造影CT(動脈相)

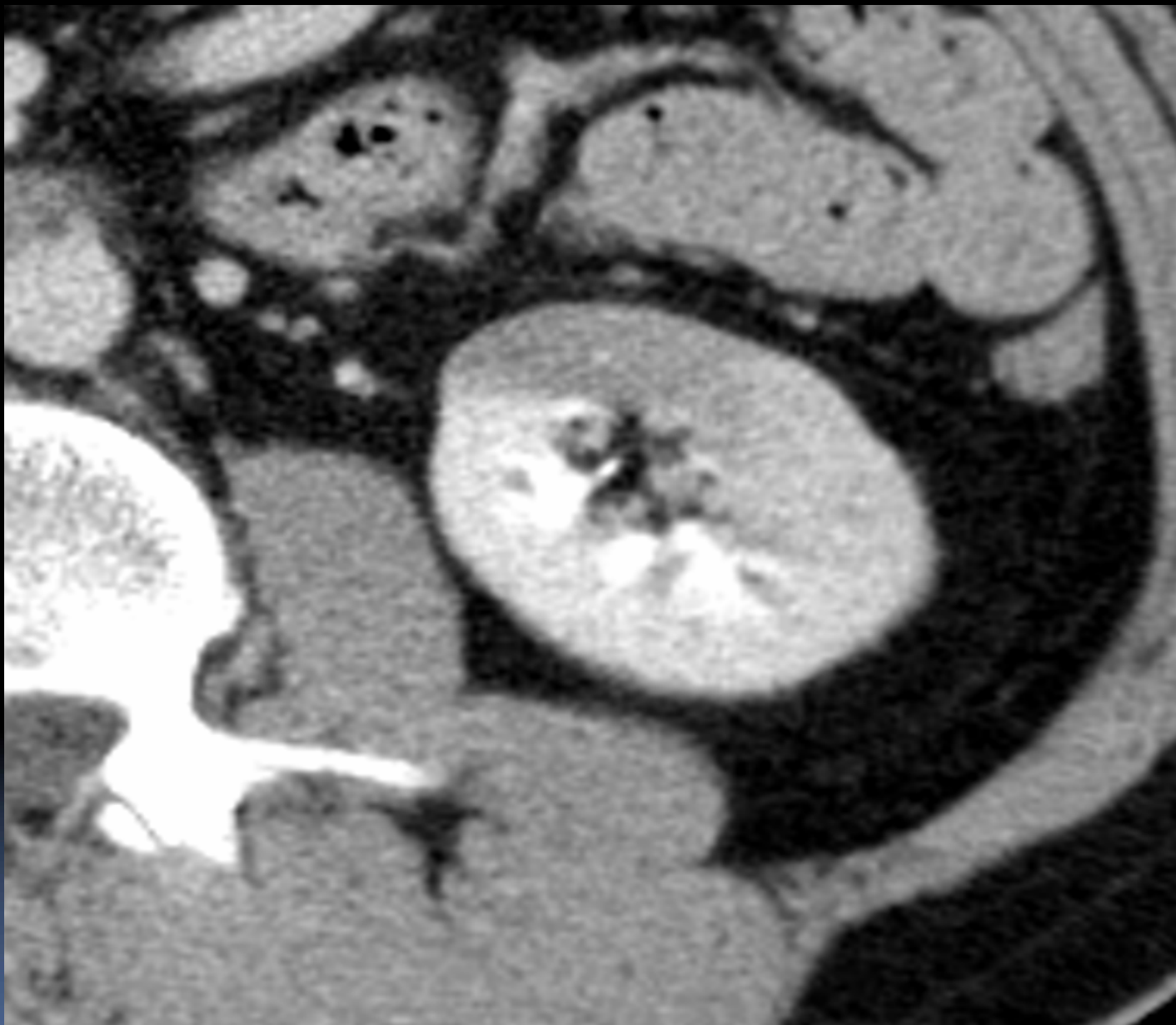


图 3 腹部造影CT(静脉相)

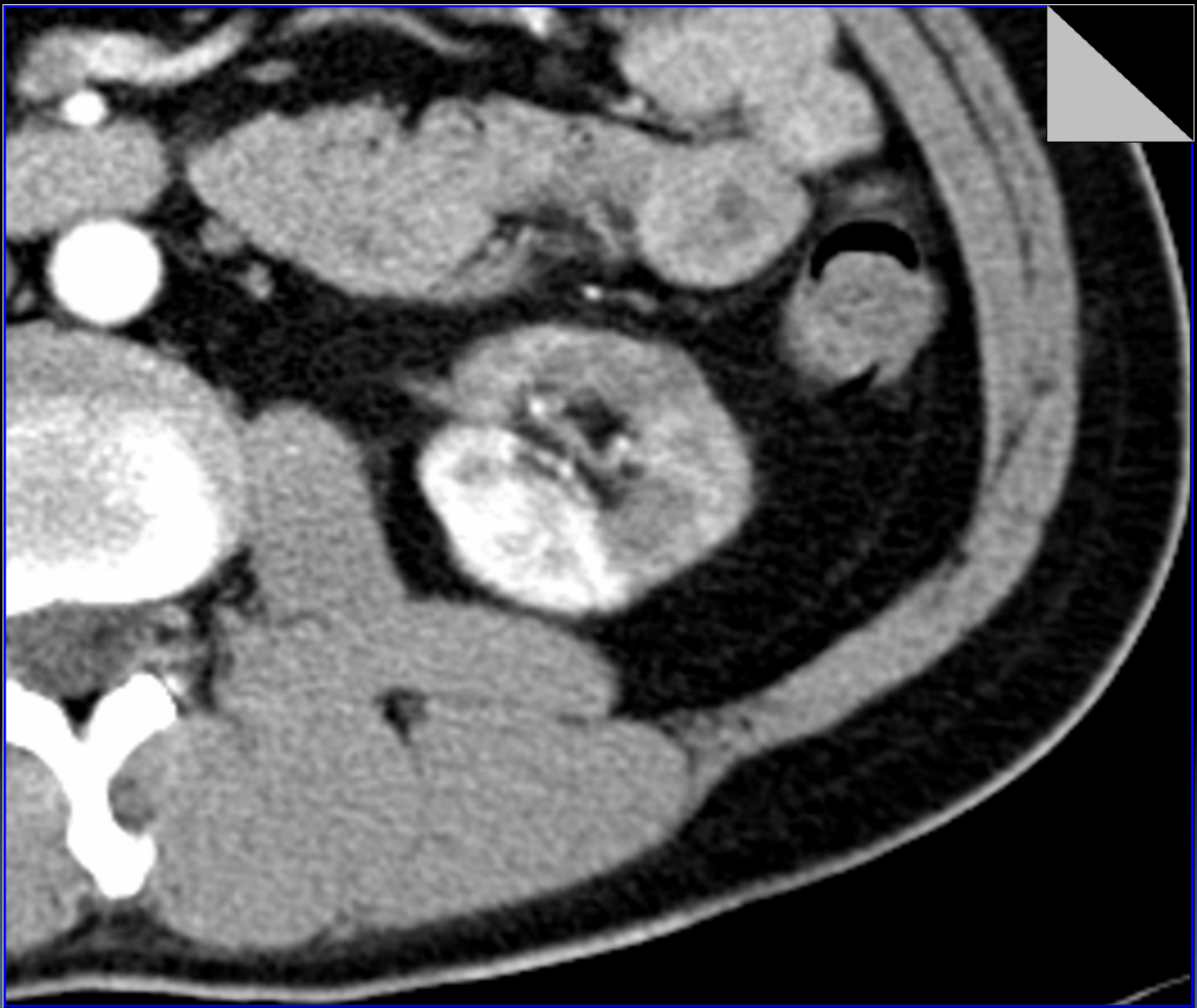

図 4 腹部造影CT(動脈相)発症1週間後