

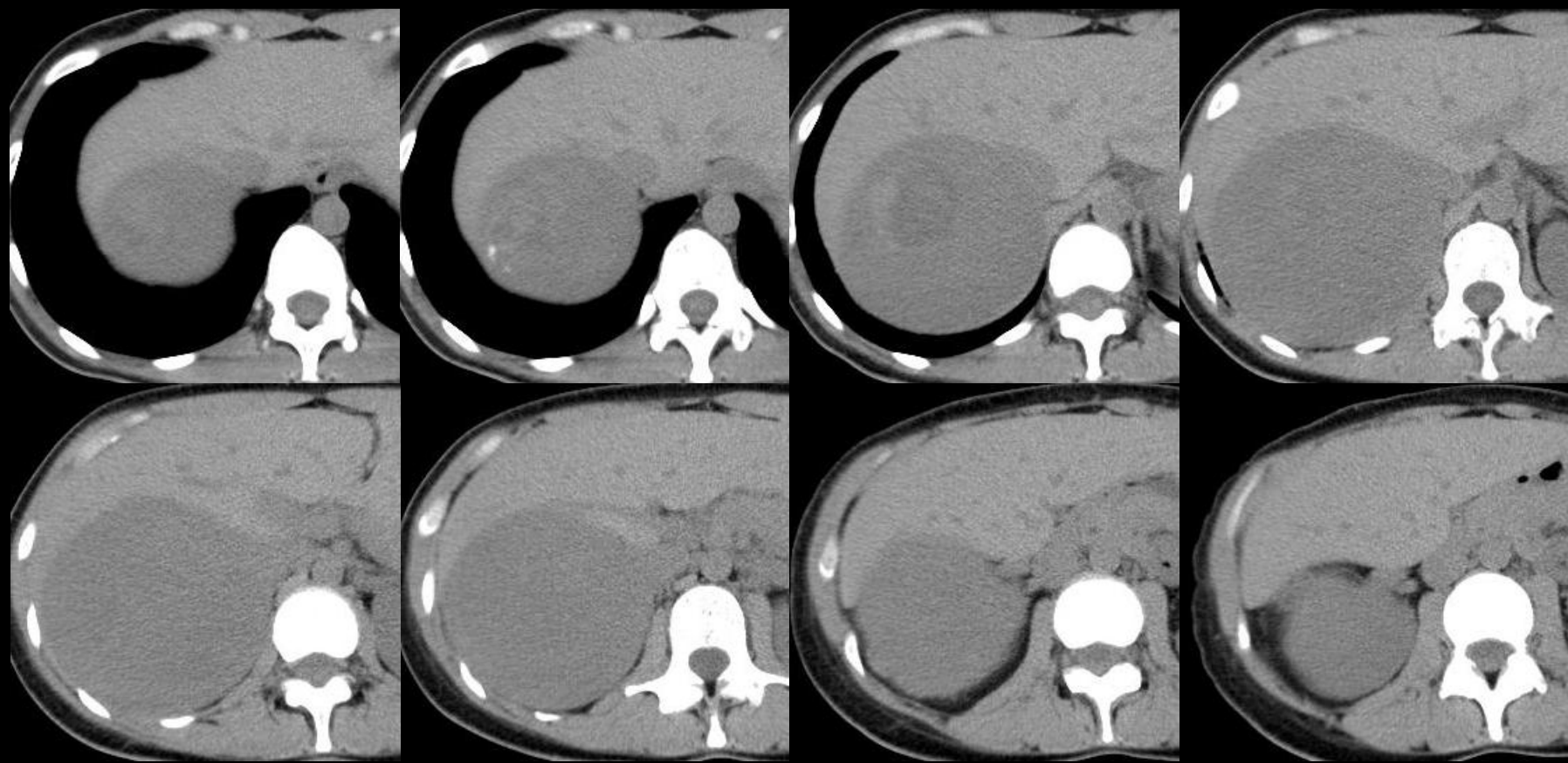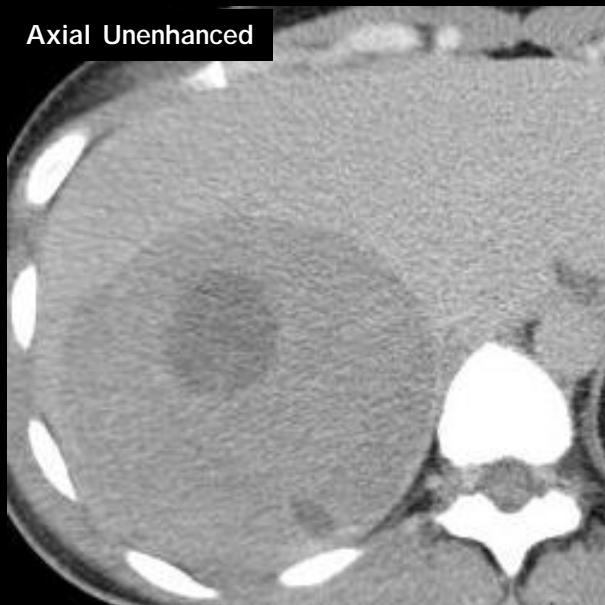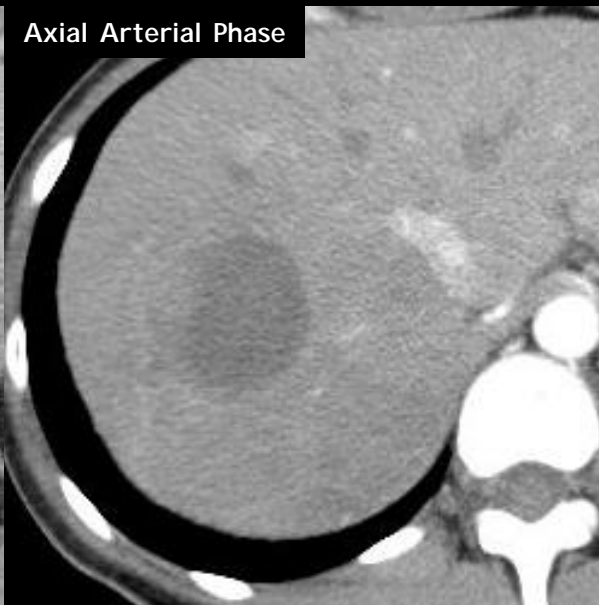图1 腹部CT(非造影)

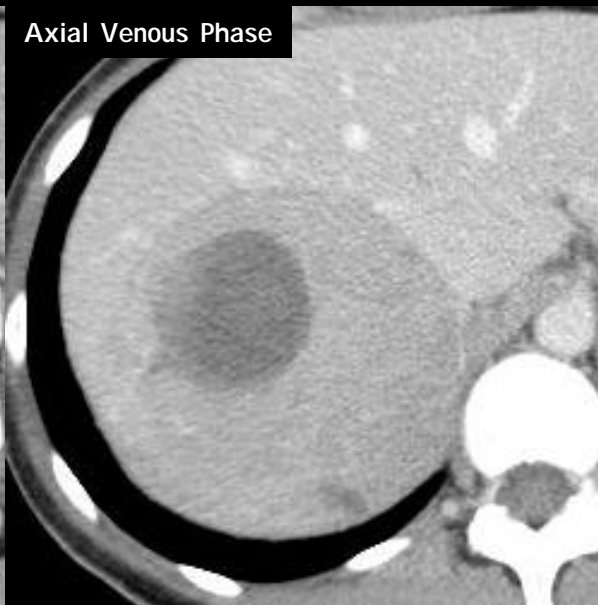Axial Unenhanced



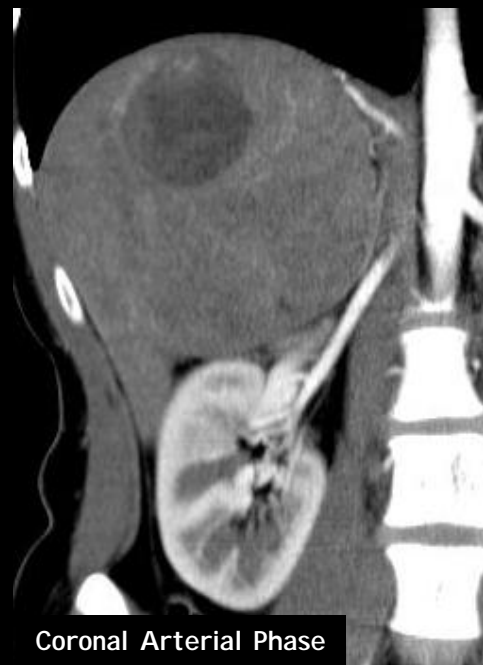Axial Arterial Phase



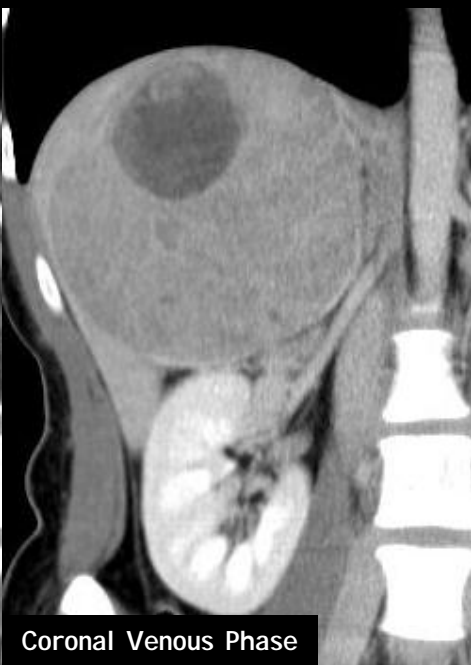Axial Venous Phase



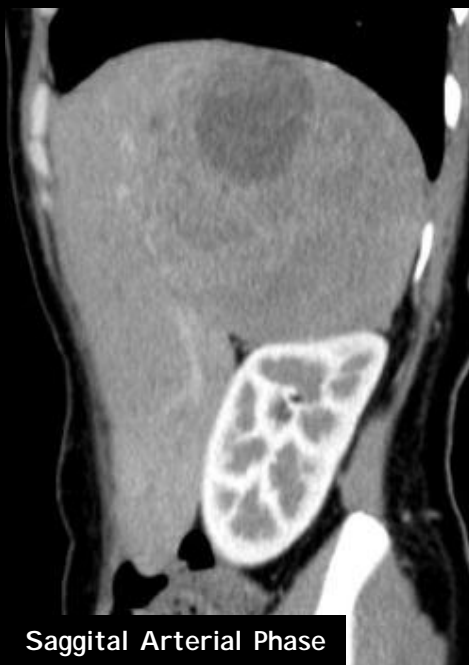Coronal Arterial Phase



Coronal Venous Phase



Sagittal Arterial Phase

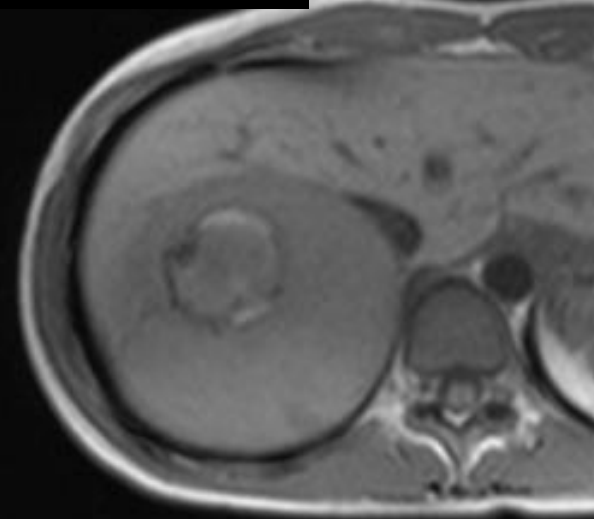


Sagittal Venous Phase

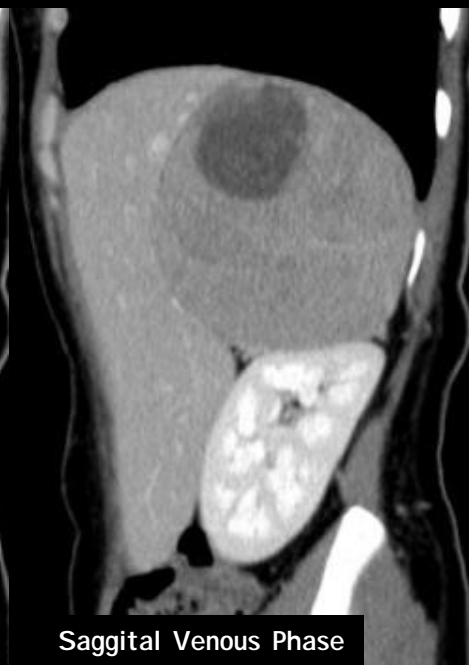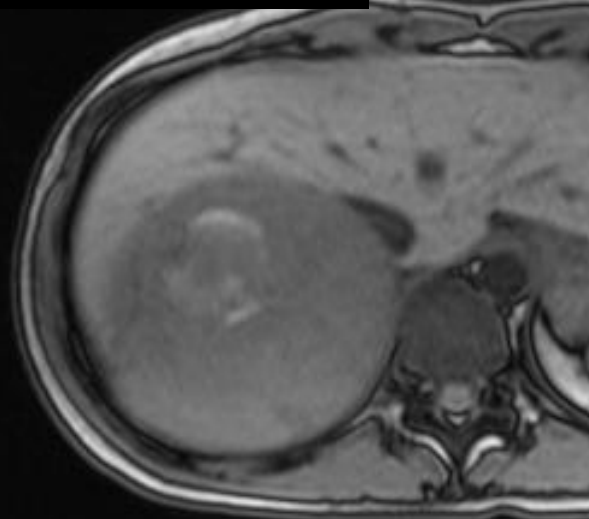


图2 腹部CT(造影)

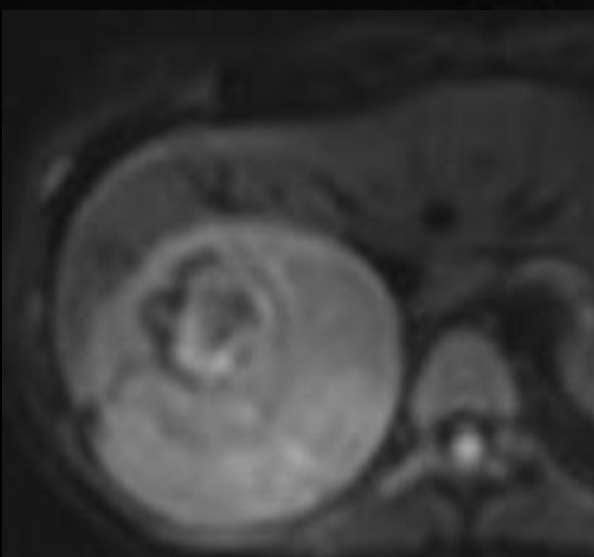
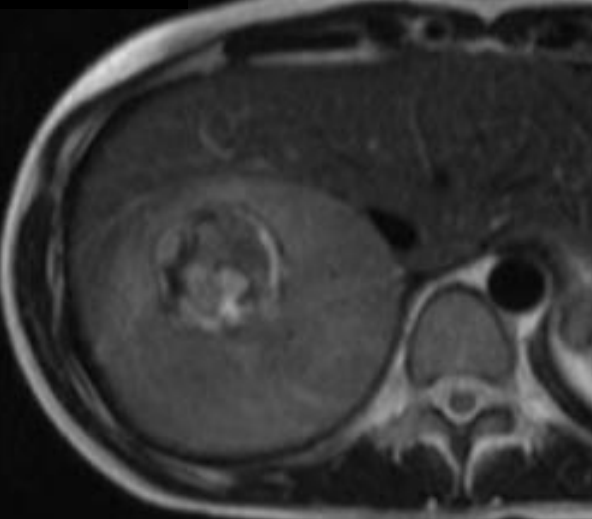
Axial T1WI in-phase



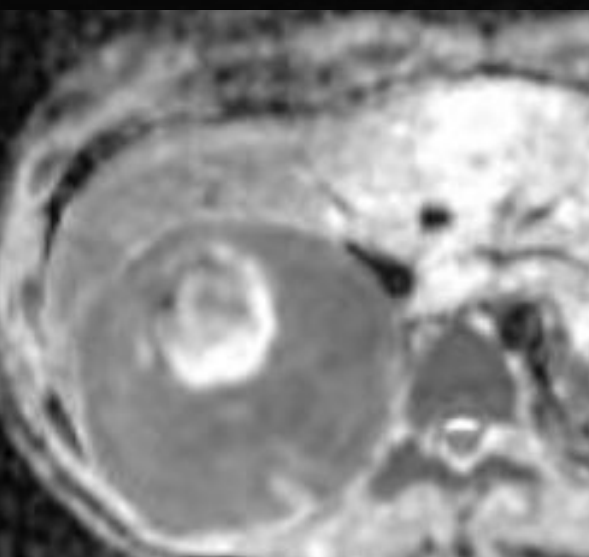
Axial T1WI out-of-phase



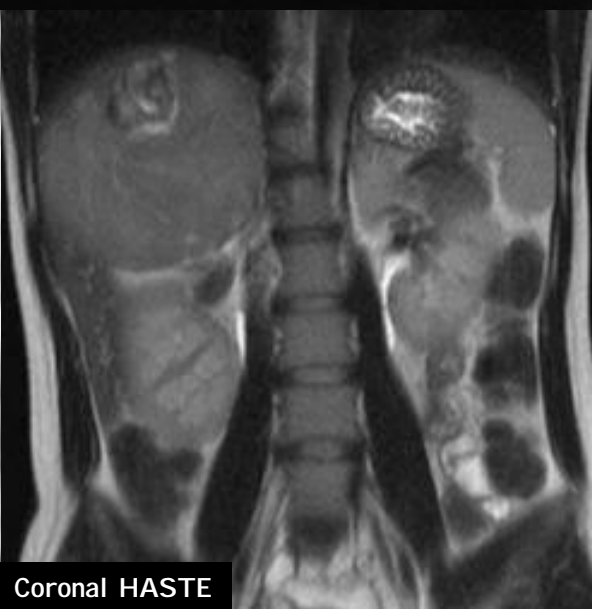Axial T2WI



Axial DWI b=800



Axial ADC map



Coronal HASTE

图3 腹部MRI

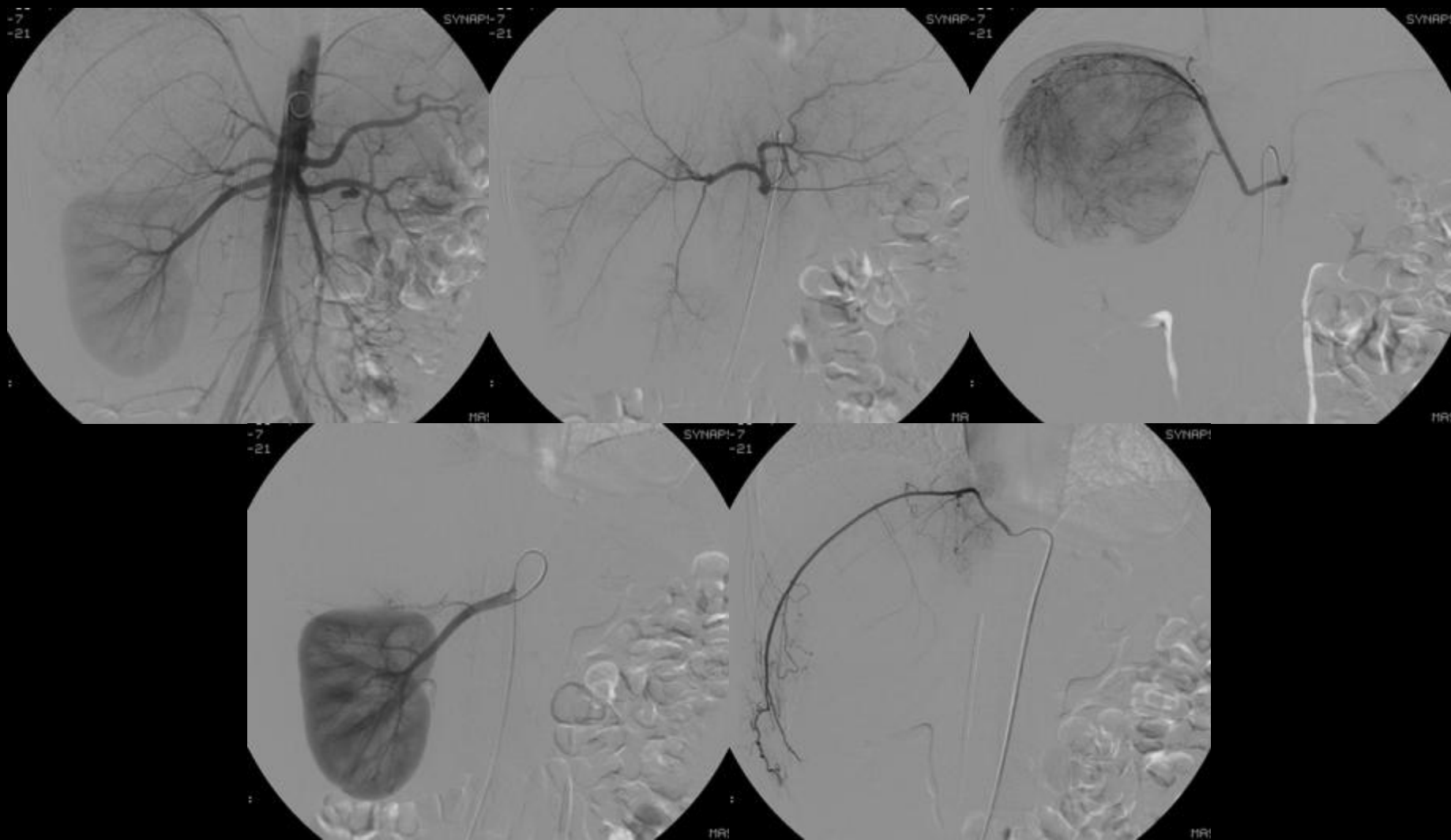


图4 血管造影